

Anterior Cruciate Ligament Reconstruction Using a Fascia Lata Graft With FiberTape Augmentation



Patrick Weninger, M.D., Caterina Steffel, B.Sc. c.m., Stefan Rabel, M.D.,
Ramin Karimi, M.D., and Xaver Feichtinger, M.D., Ph.D.

Abstract: Reconstruction of the anterior cruciate ligament (ACL) is one of the most popular orthopedic surgical procedures. To date, numerous studies are available focusing on different reconstruction techniques using established autografts, such as hamstrings, bone patellar-tendon bone (BPTB), quadriceps tendon, or allograft tendons. In the present article, we describe a minimally invasive ACL reconstruction technique using a fascia lata autograft in combination with FiberTape (Arthrex, Naples, FL) augmentation using the TightRope II (Arthrex). The minimally invasive harvesting procedure is performed by using the new QuadPro Tendon Harvester (Arthrex). This technique is recommended for acute and chronic complete ACL ruptures or bundle ruptures in athletes or patients with high physical activity. The technique might allow early full weight bearing due to less donor site morbidity, early free range of motion, and early active rehabilitation due to the use of FiberTape as a augmentation device to reinforce the autograft. Clinical studies are necessary to prove the principle.

Introduction

Annually, about 250,000 patients sustain an injury to the anterior cruciate ligament (ACL) in the United States alone.¹ Therefore, lesions of the ACL are frequent in young athletes, and physically active patients with potential long-term implications, including posttraumatic instability and consecutive meniscus and cartilage tears, leading to arthritis.^{2,3}

It is generally accepted that ACL reconstruction is the method of choice to restore knee anatomy and knee kinematics to avoid knee instability and to allow for safe return to sports in active athletes after sustaining an ACL tear. At present, different surgical techniques and various grafts are feasible for ACL reconstruction. All of them have been well investigated in numerous studies over the years. Today, hamstring autografts are the most frequently used grafts for ACL reconstruction.^{4,5}

As an alternative, bone-tendon-bone (BTB) autografts or quadriceps tendon autografts have been well described in the literature. Recently, different allografts have been suggested as another option in ACL reconstructive surgery. In acute or partial tears, direct ACL refixation techniques and internal bracing might be feasible options.⁶⁻⁸ An important factor for graft selection are donor-site morbidity, graft strength, and diameter, as well as costs, particularly with regard to allograft.⁹ The use of fascia lata for ACL reconstruction was first described by Hey-Groves in 1917.¹⁰ Technical improvements were hereinafter described by MacIntosh and by Jaeger.¹¹ Chan et al. stated on biomechanical testing a single-loop construct of fan-folded fascia lata graft performed significantly better than BTB concerning the mean ultimate load to failure and stiffness.⁹ Another recent study by Espejo-Reina describes ACL reconstruction using a combined hamstring and fascia lata graft.¹²

The aim of this article is to describe an enhanced technique for harvesting a fascia lata graft using the QuadPro Tendon Harvester for an advanced ACL reconstruction technique with FiberTape and TightRope II for graft augmentation.

Surgical Technique

Patient Position

The following technique is advised for patients with acute or chronic ACL tears. The patient is positioned in

From the Sports Medical Center, Vienna, Austria (P.W., C.S., S.R., R.K., X.F.); and Döbling Private Hospital, Vienna, Austria (P.W., R.K.).

The authors report the following potential conflicts of interest or sources of funding: P.W. is an instructor and consultant for Arthrex. Full ICMJE author disclosure forms are available for this article online, as [supplementary material](#).

Received December 22, 2021; accepted September 22, 2022.

Address correspondence to Patrick Weninger, M.D., Am Hof 11/9, 1010 Vienna, Austria. E-mail: ordination@dr-weninger.at

© 2022 THE AUTHORS. Published by Elsevier Inc. on behalf of the Arthroscopy Association of North America. This is an open access article under the CC BY-NC-ND license (<http://creativecommons.org/licenses/by-nc-nd/4.0/>).

2212-6287/2219

<https://doi.org/10.1016/j.eats.2022.09.002>

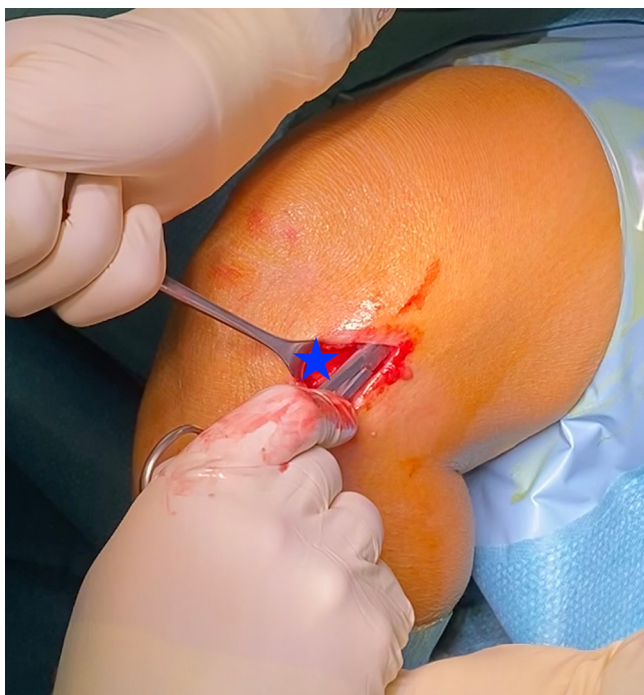


Fig 1. Left knee with patient in supine position. Minimally invasive fascia lata preparation (blue star).

standard supine position under spinal or general anesthesia. The leg is placed in a leg holder, and a tourniquet is applied. The tourniquet is positioned as far proximal on the thigh as possible and is not routinely inflated. A minimum knee flexion of 120° must be guaranteed for anteromedial (AM) portal drilling. Pre-operative single-shot antibiotic prophylaxis with cefazolin 2g IV is applied.

Diagnostic Arthroscopy

A high anterolateral or central trans-patellar-tendon portal as vision portal for ACL reconstruction and a suprameniscal anteromedial portal is recommended.⁶ After removal of blood clots, diagnostic arthroscopy is performed with a standard 30° optic device. If there are any concomitant intra-articular injuries, they are assessed and treated in that phase.

Graft Harvesting

An approximately 2-cm longitudinal skin incision is performed directly distal to the lateral femoral

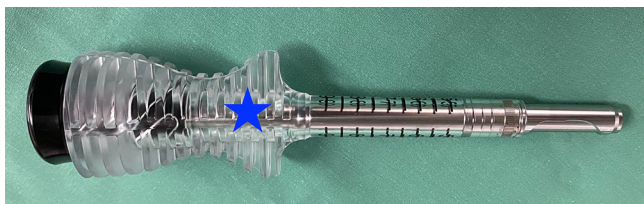


Fig 2. QuadPro tendon harvester (Arthrex, Naples, FL) (blue star) is used for fascia lata graft harvesting.

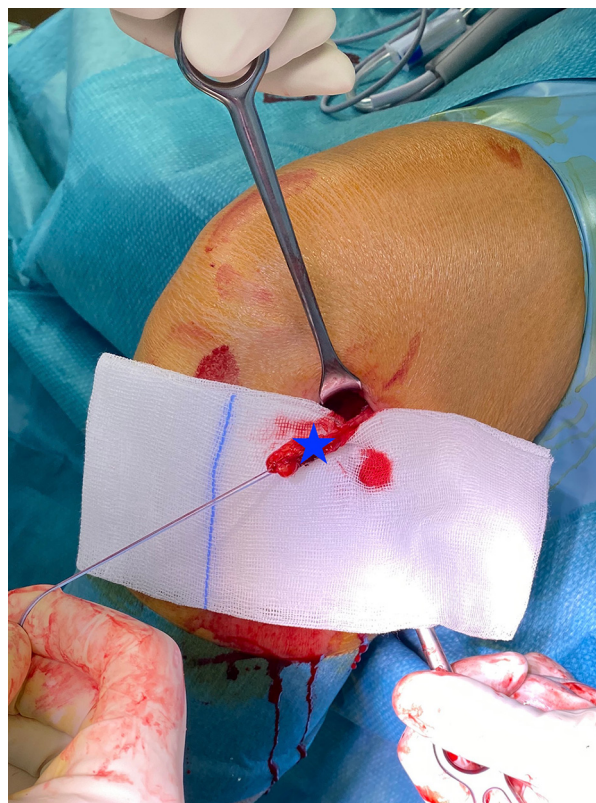


Fig 3. Left knee with patient in supine position. Tagged graft (blue star) with nonabsorbable sutures.

epicondyle. To clear soft tissue proximally and distally from the graft, a gauze is used on a Kocher-forceps. (Fig 1) Two Langenbeck retractors are then used to provide good visualization on the fascia lata. To approximate the graft width, the QuadPro Tendon Harvester (Fig 2) is placed on the fascia lata, and with the scalpel, a 10-mm wide central strip is prepared for 2-3 cm in length. The distal end of the graft is armed with a nonabsorbable no 2 FiberWire (Arthrex) to maintain tension on the graft during harvesting (Fig 3). The sutures are then pulled through the QuadPro Tendon Harvester aperture, and the fascia lata is pulled into the tip of the harvester ensuring the no 2 FiberWire suture is not cut by the tip of the harvester. The QuadPro Tendon harvester is then pushed up the fascia lata under steady tension. We recommend a graft length of approximately 15 cm to allow for a 7-cm long graft after preparation. The fascia lata graft is retrieved through the graft amputation window, and the push rod is inserted into the harvester to amputate the graft (Fig 4) (Video 1).

Graft Preparation

The harvested graft is twisted longitudinally to further increase mechanical strength of the graft and fixed on both sides with tissue clamps on the Graft Preparation System. Each end is prepared with nonabsorbable no. 2

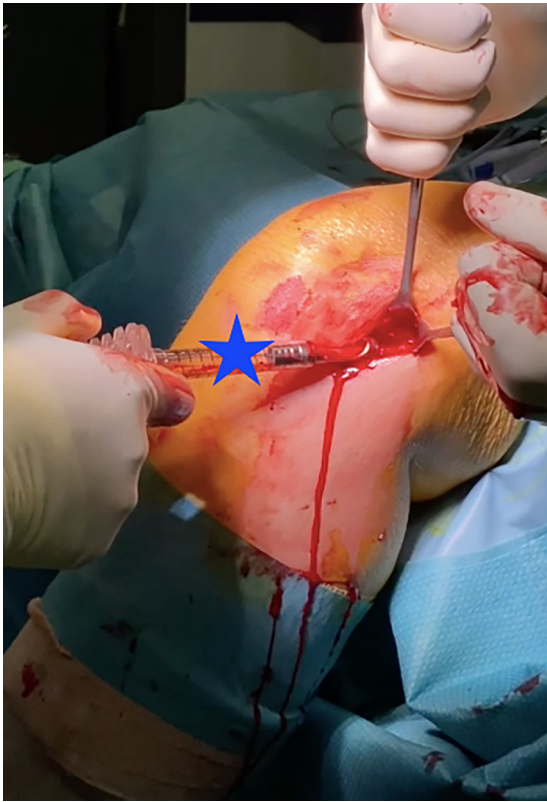


Fig 4. Left knee with patient in supine position. Minimally invasive graft harvesting with the QuadPro tendon harvester (Arthrex) (blue star).

FiberWire using baseball whip-stitches. The prepared graft is then folded and doubled (Figs 5 and 6). The graft is passed through the ACL TightRope RT loop (Arthrex) and is augmented with a 2-mm FiberTape, which is also passed through the loop (Fig 7). Alternatively, the TightRope II with integrated FiberTape can be used (Fig 8). The graft is routinely presoaked in a vancomycin solution, as described by Naendrup et al. and Pérez-Prieto et al.^{13,14} Alternatively, to the above-described, two-strand technique, the graft can also be

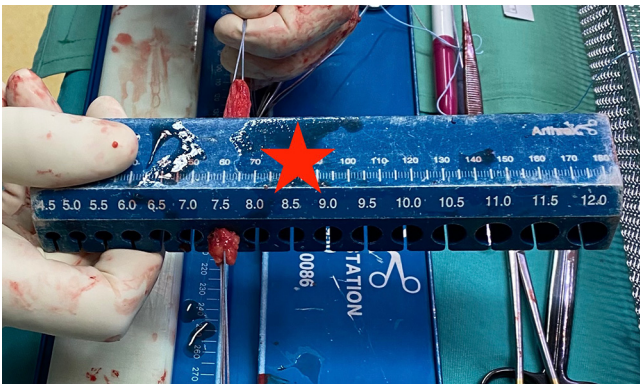


Fig 5. Left knee with patient in supine position. Measurement of the prepared graft diameter (red star).

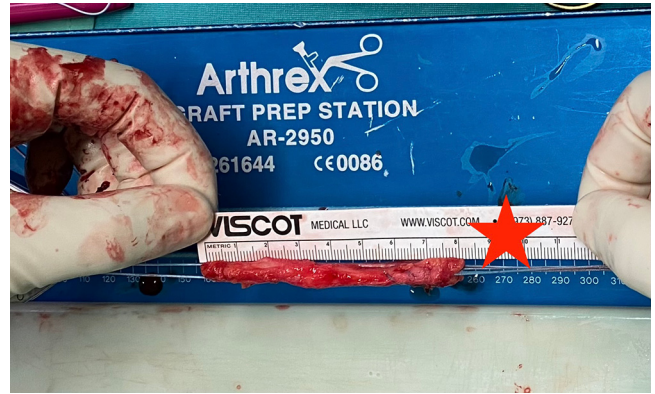

Fig 6. Left knee with patient in supine position. Measuring (red star) of the graft length.

prepared as a three-folded graft if a minimum length of 21 cm can be harvested to get a graft length of 7 cm.

Anatomic Tunnel Preparation and Graft Fixation

First the remnants of the torn ACL are removed with the knee in 90° of flexion. The 30° microfracture awl is passed through the AM portal to mark the anatomic center of the proposed femoral bone tunnel. The tunnel is placed between the AM and posterolateral (PL) bundle footprint approximately 5-7 mm anterior to the posterior cortex, according to anatomy. A 4-mm drill pin (Arthrex) is advanced through the anteromedial portal to the marked starting point. The femoral tunnel is placed with the knee flexed to at least 120° advancing the drill pin through the lateral cortex. The drill pin is then overdrilled in 120° flexion of the knee with a cannulated reamer, according to the graft diameter. A graft passing suture is passed through the eyelet of the drill pin and arranged for later retrieval and graft passage (Fig 9). Bone debris in the femoral socket is removed with the shaver. Then, the tibial tunnel is prepared (Fig 10). We use the tibial aiming device adjusted 55° (Arthrex) to prepare the tibial tunnel with the knee flexed at 90°. The aimer is placed through the AM portal on the tibial footprint medial to the tibial

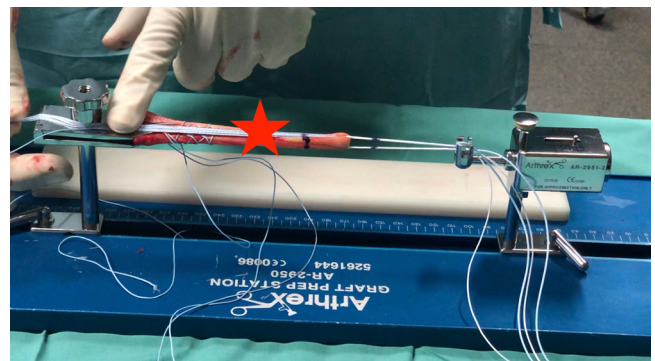

Fig 7. Pretensioning of the TightRope RT with graft and FiberTape (Arthrex) (red star).

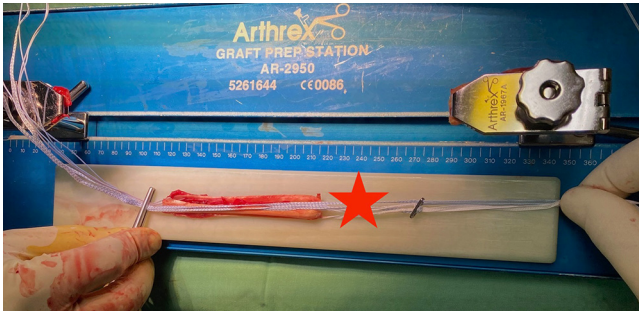


Fig 8. Pretensioning of the TightRope II (red star) with graft and FiberTape (Arthrex).

tubercle. The aiming pin is placed through the anatomic tibial footprint. Tunnel drilling is performed, according to graft size with the cannulated reamer. The tunnel is prepared with the shaver to avoid soft tissue impingement. The KingFisher (Arthrex) is used to pull out the passing suture through the tibial tunnel for transtibial graft shuttling. Via the passing suture, the ACL Tight-rope RT loaded with the graft and the 2-mm FiberTape or the TightRope II with FiberTape for augmentation is pulled through the tunnels, and the TightRope button is flipped on the lateral femoral cortex for fixation (Fig 11). The knee is cycled 10-15 times to precondition the graft. Tibial graft fixation is achieved with the knee flexed to 30°. Under continuous tension on the no. 2 FiberWire a FastThread Interference Screw (Arthrex) is used for tibial graft fixation. After arthroscopy visualization and control of free range of motion, intracutaneous skin closure is performed (Fig 12). We do not recommend an intra-articular suction drainage.

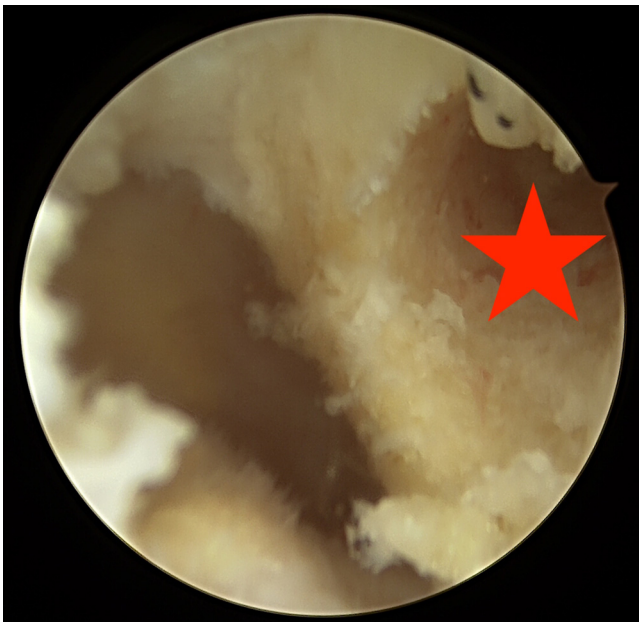

Fig 9. Left knee with patient in supine position. Arthroscopic view via central portal of the femoral bone tunnel (red star).

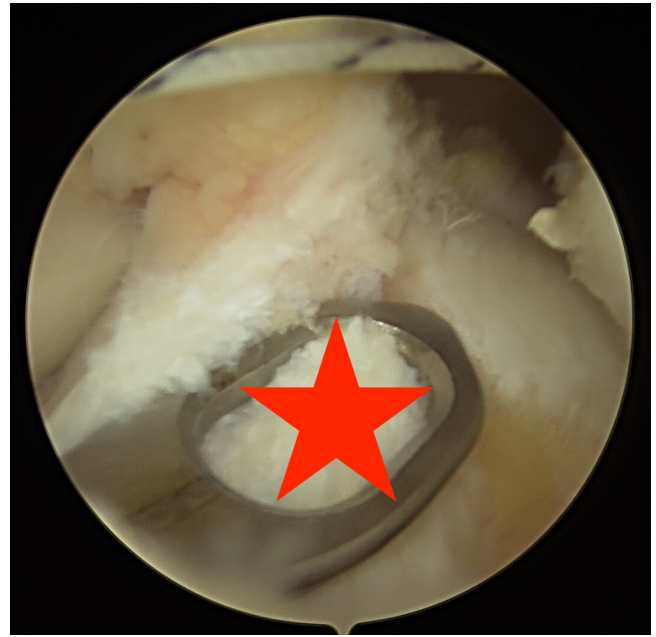


Fig 10. Left knee with patient in supine position. Arthroscopic view via central portal of the tibial bone tunnel (red star).

Step-by-Step Description of the Technique

1. The patient is placed in a supine position and then draped. The tourniquet is applied but not routinely inflated.
2. After arthroscopic verification of all intra-articular injuries, possible meniscus/cartilage tears are addressed.

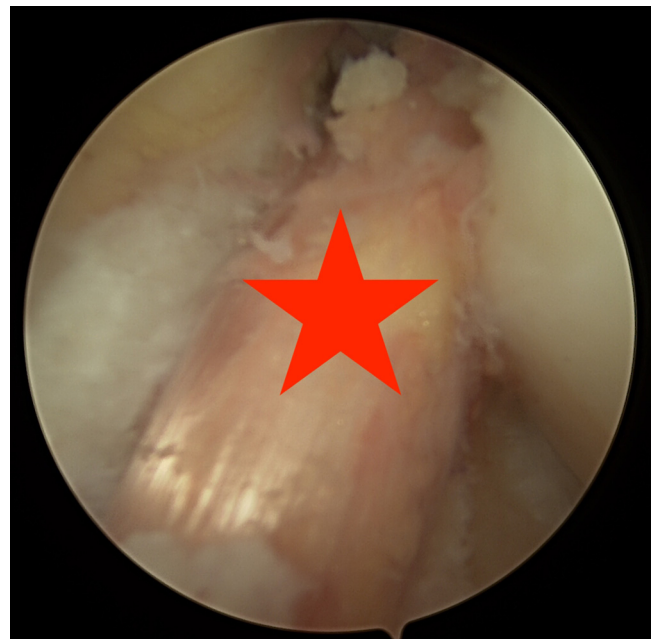

Fig 11. Left knee with patient in supine position. Arthroscopic view via central portal of the fascia lata graft in situ (red star).

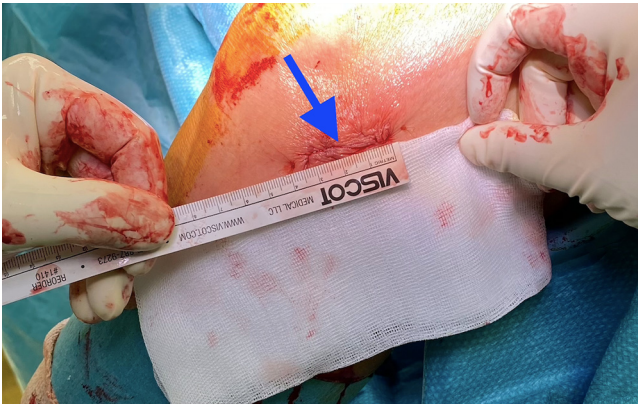


Fig 12. Left knee with patient in supine position. Skin wound closure (blue arrow).

3. Over a 2-cm longitudinal skin incision, the 9-mm wide fascia lata strip is harvested with the QuadPro Tendon Harvester (Video 1).
4. The graft is then prepared on the preparation board: no. 2 FiberWire sutures are attached on both ends of the 16-cm fascia lata graft. Then the graft is folded (doubled) within the loop of the ACL TightRope RT. Additionally, a 2-mm FiberTape is routinely inserted through the loop to enforce the tendon graft. The graft is then pretensioned and coated with vancomycin by using a soaked gauze.
5. Then the femoral (from anteromedial) and the tibial tunnel tunnels are drilled, and the graft is inserted and femorally secured with the Tight Rope RT. For tibial fixation, the FastThread Interference Screw will be used.

Postoperative Treatment

Patients undergoing ACL reconstruction are routinely discharged from the hospital on the same day or on the first postoperative day. Immediate supervised physical rehabilitation starts on the day of discharge. We recommend instant full weight-bearing exercises and free range of motion as tolerated.¹⁵ In the early postoperative phase of rehabilitation compression and cryotherapy via the full leg boot (Game Ready, Cool-Systems, Inc., Concord, California) is applied within 3 days postsurgery. Within 4 weeks, we recommend

closed kinetic-chain exercises followed by open kinetic-chain exercise. Supplementary focused extra corporal shock wave therapy (STORZ Medical, Tägerwil, Switzerland) is applied once a week for four times.¹⁶

Discussion

Table 1 shows pearls and pitfalls about the above-described technique (Table 1). The fascia lata as potential graft for ACL reconstruction or augmentation has been consistently described in the last decades.¹⁷ A study by Ekstrand et al. published in 1989 outlined good clinical and functional outcomes using a fascia lata stripe for ACL reconstruction. From the technical point of view, this technique is more invasive, and the postoperative regime is more restrictive compared to the above-described technique.¹⁸ For revision ACL reconstruction Mirouse et al. noted that fascia lata graft provides similar return-to-sports rates as other common techniques.¹⁹ In a biomechanical study, Chan et al. pointed out that a single loop fan-folded fascia lata allograft has at least the equivalent initial ultimate tensile strength and stiffness values than several other grafts such as BTB.⁹

In comparison to common autografts harvesting, a fascia lata graft causes less donor-site morbidity, such as tenderness, anterior knee pain, and impairment in anterior knee sensitivity. In addition, there is less disturbance of the muscular strength and the range of motion, which is often described using a quadriceps or hamstring graft.²⁰

Xergia et al. reported an obvious trend toward quadriceps muscle weakness when using a BTB graft, as well as a trend for hamstrings deficit using a hamstrings tendon graft.²¹ The preservation of muscular balance between the flexor and extensor mechanism in the leg using a fascia lata graft is close to physiological norms. In consideration of the fact that 80% or more of the strength in the quadriceps and hamstrings is needed to preserve the graft when returning to sports after ACL reconstruction,²² the fascia lata graft with FiberTape augmentation is a promising graft to enable a shortened back-to-sports period. To confirm this hypothesis, further clinical studies are needed.

The QuadPro Tendon harvester allows for minimally invasive harvesting of a fascia lata stripe through a

Table 1. Pearls and Pitfalls

Pearls	Pitfalls and Risks
Less donor site morbidity	Possibility of muscular hernia
No muscular deficit	Too short graft if not carefully performed
Less skin sensory deficit	Possible difficulty in harvesting and dissection of the fascia lata when the tourniquet is inflated
Versatile graft for individualized ACL repair (graft diameter, graft length, two-fold, or three-fold)	
Early full weight bearing (FiberTape augmentation)	
Minimally invasive harvesting (small scars)	

small skin incision with decreased donor site morbidity. However, it must be noted that there is some danger of harvesting a graft that might be too short if graft amputation with the QuadPro Tendon harvester is not carefully performed.

The correct graft preparation is an important step to generate a sufficient implant in length and diameter. We regularly use a FiberTape augmentation in hamstring and quadriceps tendon autografts, which we strongly recommend, especially if the graft diameter is less than 8 mm.

It needs to be highlighted that the senior author of the present technique has routinely used FiberTape augmentation for the past 3 years and has evaluated more than 1,000 patients using this technique so far. Currently, a clinical study has been initiated regarding ACL reconstruction using fascia lata graft with FiberTape augmentation. Using this technique, we can report only two cases of rerupture of the ACL graft. Opponents might point out potential side effects of intra-articular use of FiberTape. In a recent study by Weninger et al., the authors used FiberTape augmentation in 40 patients, finding not a single case of synovitis or other foreign body reactions. In that context, our minimally invasive surgical technique combined with FiberTape augmentation demonstrates progress in using the fascia lata as a primary graft for ACL reconstruction.

It has to be noted that development of a muscular hernia can occur as a potential side effect. To avoid such an outcome, we recommend minimally invasive fascial closure according to Lavender et al.²³ It should also be mentioned that harvesting and dissection of the fascia lata from the vastus lateralis muscle can be difficult if the tourniquet is inflated.

This article provides an additional option for ACL reconstruction. To validate the above-described surgical technique regarding long-term outcome, further clinical studies are necessary.

In our opinion using a fascia lata graft, especially in combination with FiberTape, as described in this article, seems to be an ideal way to repair a torn ACL with regard to donor site morbidity, postoperative pain, development of hematoma, and swelling and muscular weakening.

References

- Collins JE, Katz JN, Donnell-Fink LA, Martin SD, Losina E. Cumulative incidence of ACL reconstruction after ACL injury in adults: role of age, sex, and race. *Am J Sports Med* 2013;41:544-549.
- Krause M, Freudenthaler F, Frosch KH, Achtnich A, Petersen W, Akoto R. Operative versus conservative treatment of anterior cruciate ligament rupture. *Dtsch Arztebl Int* 2018;115:855-862.
- Kijowski R, Roemer F, Englund M, Tiderius CJ, Swärd P, Frobell RB. Imaging following acute knee trauma. *Osteoarthritis Cartilage* 2014;22:1429-1443.
- Yucens M, Aydemir AN. Trends in anterior cruciate ligament reconstruction in the last decade: A web-based analysis. *J Knee Surg* 2019;32:519-524.
- Jagadeesh N, Dhawan T, Sheik F, Shivalingappa V. Does hamstring graft size affect functional outcome and incidence of revision surgery after primary anterior cruciate ligament (ACL) reconstruction? *Cureus* 2022;14, e21158.
- Weninger P, El Marto S, Thallinger C, Karimi R, Feichtinger X. Advanced anterior cruciate ligament repair and reconstruction techniques for different rupture types. *Arthroscopy Techniques* 2020;9:e969-e977.
- Hopper GP, Aithie JMS, Jenkins JM, Wilson WT, Mackay GM. Combined anterior cruciate ligament repair and anterolateral ligament internal brace augmentation: Minimum 2-year patient-reported outcome measures. *Orthop J Sports Med* 2020;8, 2325967120968557.
- Irfan A, Kerr S, Hopper G, Wilson W, Wilson L, Mackay G. A Criterion-based rehabilitation protocol for ACL repair with internal brace augmentation. *Int J Sports Phys Ther* 2021;16:870-878.
- Chan DB, Temple HT, Latta LL, Mahure S, Dennis J, Kaplan LD. A biomechanical comparison of fan-folded, single-looped fascia lata with other graft tissues as a suitable substitute for anterior cruciate ligament reconstruction. *Arthroscopy* 2010;26:1641-1647.
- Burnett QM, Fowler PJ. Reconstruction of the anterior cruciate ligament: Historical overview. *Orthop Clinics N A* 1985;16:143-157.
- Khiami F, Wajsfisz A, Meyer A, Rolland E, Catonné Y, Sariali E. Anterior cruciate ligament reconstruction with fascia lata using a minimally invasive arthroscopic harvesting technique. *Orthop Traumatol Surg Res* 2013;99:99-105.
- Espejo-Reina A, Espejo-Reina MJ, Lombardo-Torre M, Ruiz-Del Pino J, Espejo-Baena A. Anterior cruciate ligament reconstruction using combined graft of hamstring and fascia lata with extra-articular tenodesis. A technique in case of insufficient hamstrings. *Arthrosc Tech* 2020;9: e1657-e1663.
- Naendrup JH, Marche B, de Sa D, et al. Vancomycin-soaking of the graft reduces the incidence of septic arthritis following ACL reconstruction: Results of a systematic review and meta-analysis. *Knee Surg Sports Traumatol Arthrosc* 2020;28:1005-1013.
- Pérez-Prieto D, Torres-Claramunt R, Gelber PE, Shehata TMA, Pelfort X, Monllau JC. Autograft soaking in vancomycin reduces the risk of infection after anterior cruciate ligament reconstruction. *Knee Surg Sports Traumatol Arthrosc* 2016;24:2724-2748.
- Andrade R, Pereira R, van Cingel R, Staal JB, Espregueira-Mendes J. How should clinicians rehabilitate patients after ACL reconstruction? A systematic review of clinical practice guidelines (CPGs) with a focus on quality appraisal (AGREE II). *Br J Sports Med* 2020;54:512-519.
- Wang CJ, Ko JY, Chou WY, Hsu SL, Ko SF, Huang CC, et al. Shockwave therapy improves anterior cruciate ligament reconstruction. *J Surg Res* 2014;188:110-118.
- Espejo-Reina A, Espejo-Reina MJ, Lombardo-Torre M, Ruiz-Del Pino J, Espejo-Baena A. Anterior cruciate ligament reconstruction using combined graft of hamstring and fascia lata with extra-articular tenodesis. A technique

- in case of insufficient hamstrings. *Arthrosc Tech* 2020;9:e1657-e1663.
18. Ekstrand J. Reconstruction of the anterior cruciate ligament in athletes, using a fascia lata graft: A review with preliminary results of a new concept. *Int J Sports Med* 1989;10:225-232.
 19. Mirouse G, Rousseau R, Casabianca L, et al. Return to sports and functional results after revision anterior cruciate ligament reconstruction by fascia lata autograft. *Orthop Traumatol Surg Res* 2016;102:863-866.
 20. Kartus J, Movin T, Karlsson J. Donor-site morbidity and anterior knee problems after anterior cruciate ligament reconstruction using autografts. *Arthroscopy* 2001;17:971-980.
 21. Xergia SA, McClelland JA, Kvist J, Vasiliadis HS, Georgoulis AD. The influence of graft choice on isokinetic muscle strength 4-24 months after anterior cruciate ligament reconstruction. *Knee Surg Sports Traumatol Arthrosc* 2011;19:768-780.
 22. Hailotte G, Hardy A, Granger B, Noailles T, Khiami F. Early strength recovery after anterior cruciate ligament reconstruction using the fascia lata. *Orthop Traumatol Surg Res* 2017;103:1021-1025.
 23. Lavender C, Fravel W, Patel T, Singh V. Minimally invasive quad harvest featuring endoscopic closure and preparation with adjustable suspensory fixation device incorporated with braided suture. *Arthrosc Tech* 2021;10:e217-e220.